



Arquivo Brasileiro de Medicina Veterinária e Zootecnia

Publication of: **Universidade Federal de Minas Gerais, Escola de Veterinária**
Area: Agricultural Sciences
ISSN printed version: 0102-0935
ISSN online version: 1678-4162
Previous title Arquivos da Escola Veterinária da Universidade Federal de Minas Gerais

[Submission of manuscripts](#)[About the journal](#)[Política editorial](#)[Editorial Board](#)[Instructions to authors](#)[Contact](#)[Journal homepage](#)[All issues](#)[« Previous issue](#)[Next issue »](#)[Current issue](#)[Metrics](#)

[Home](#) / [Journals](#) / [Arquivo Brasileiro de Medicina Veterinária e Zootecnia](#) / [Table of contents](#)

Table of contents

Arquivo Brasileiro de Medicina Veterinária e Zootecnia, Volume: 76, Issue: 2, Published: 2024

VETERINARY MEDICINE AND TECHNOLOGY AND INSPECTION OF ANIMAL PRODUCTS

Bone adaptation to exercise in Arab horses practicing enduro equestrian 120-160km - quantitative and functional analysis

Rajão, M.D. Leite, C.S. Barreto-Vianna, A.R.C. Lima, E.M.M.

Abstract: [EN](#) [PT](#) Text: [EN](#) PDF: [EN](#)

VETERINARY MEDICINE AND TECHNOLOGY AND INSPECTION OF ANIMAL PRODUCTS

Prevalence of equine infectious anemia virus in horses and donkeys determined by comparison of ELISA and AGID in Mexico

Villa-Mancera, A. Villegas-Bello, L. Campos-García, H. Ortega-Vargas, S. Cruz-Aviña, J. Patricio-Martínez, F. Olivares-Pérez, J. Utrera-Quintana, F.

Abstract: [EN](#) [PT](#) Text: [EN](#) PDF: [EN](#)

VETERINARY MEDICINE AND TECHNOLOGY AND INSPECTION OF ANIMAL PRODUCTS

Acute phase proteins, hematological and serum biochemical profiles of female dogs in diestrus, mucometra and pyometra

Friolani, M. Santana, A.M. Voorwald, F. A. Almeida, L.A. Padilha-Nakaghi, L.C. Silva, D.G. Costa, I.B. Fagliari, J.J. Toniollo, G.H.

Abstract: [EN](#) [PT](#) Text: [EN](#) PDF: [EN](#)

VETERINARY MEDICINE AND TECHNOLOGY AND INSPECTION OF ANIMAL PRODUCTS

Evaluation of maternal antibodies against parvovirus in puppies with vaccinated and unvaccinated bitches in Mazandaran Province, Iran

Aghabeigi, P. Khaksar, E. Bokaie, S.

Abstract: [EN](#) [PT](#) Text: [EN](#) PDF: [EN](#)

VETERINARY MEDICINE AND TECHNOLOGY AND INSPECTION OF ANIMAL PRODUCTS

Multicentric peripheral T-cell lymphoma, bilateral granulosa cell tumor, and papillary ovarian adenocarcinoma in a female dog - case report
Wronski, J.G. Nakagaki, K.Y.R. Viscone, E.A. Nunes, M.M. Cassali, G.D.

Abstract: EN PT **Text:** EN **PDF:** EN

VETERINARY MEDICINE AND TECHNOLOGY AND INSPECTION OF ANIMAL PRODUCTS

Lip lesions in horses: case report
Kulnych, S. Jaśkowski, J. Zvenihorodska, T. Kolomak, I. Tul, O.

Abstract: EN PT **Text:** EN **PDF:** EN

VETERINARY MEDICINE AND TECHNOLOGY AND INSPECTION OF ANIMAL PRODUCTS

Pneumonia, airsacculitis and osteomyelitis caused by *Aspergillus fumigatus* in an African grey parrot (*Psittacus erithacus*) - case report
Souza, L.R. Santana, C.H. Ribeiro, L.N. Sousa, D.R. Gomes, K.M.C. Barroca, J.M.J.F. Silva, M.B.G. Santos, R.L.

Abstract: EN PT **Text:** EN **PDF:** EN

VETERINARY MEDICINE AND TECHNOLOGY AND INSPECTION OF ANIMAL PRODUCTS

Anatomical and ultrasonographic characteristics of testicular abscesses and testicular microlithiasis: a case study of 5 kazakh rams
Dong, D. Su, Z. Jiang, L. Ai, H. Liu, X.

Abstract: EN PT **Text:** EN **PDF:** EN

ANIMAL SCIENCE

Possibilities of using cubic spline function and yield-density models in estimation of live weight of kıvırcık lambs fed with different silage types
Şengül, Ö. Çelik, Ş. Ak, İ.

Abstract: EN PT **Text:** EN **PDF:** EN

ANIMAL SCIENCE

Canopy structure, behavioral and physiological aspects of pasture-finished sheep using castor bean cake as alternative input
Meneses, A.J.G. Pompeu, R.P.F.F. Salles, H.O. Farias, A.S.S. Nenem, L.H.S. Costa, C.S. Guedes, L.F. Maranguape, J.S. Pereira, P.L. Cândido, M.J.D.

Abstract: EN PT **Text:** EN **PDF:** EN

ANIMAL SCIENCE

Effects of maternal factors and season on health, growth and reproductive parameters in Holstein young heifers
Silva, K.N. Madureira, K.M. Bosco, K.A. Morita, L.M. Nichi, M. Gomes, V.

Abstract: EN PT **Text:** EN **PDF:** EN



Lip lesions in horses: case report

[Lesões labiais em cavalos: relato de caso]

S. Kulynych¹ , J. Jaśkowski² , T. Zvenihorodska^{1*} , I. Kolomak¹ , O. Tul¹ 

¹Poltava State Agrarian University, 1/3, Skovorody str., Poltava, 36003, Ukraine

²Nicolaus Copernicus University in Torun, Gagarina 11 str., 87 100 Torun, Poland

ABSTRACT

The article presents the results of monitoring studies on the mucous membrane lesions in Trakehner horses. Based on clinical examination, the localization, size, and number of ulcers, as well as the inflammatory reaction to the presence of necrotic tissue, were determined. In addition to clinical examination, planimetric studies were also carried out to determine the size of the ulcers and the dynamics of their reduction during treatment with aerosol application of PVP iodine spray. To determine the nature of inflammation in the lesion focus, smears were taken from the surface of the ulcers. Microbiological and mycological studies of pathological tissues and feed samples were carried out to establish the etiological factors contributing to the ulcers. It was found that the size of the ulcers varied from 1 to 6 cm, and they were located on the upper and lower lips on both the right and left sides. Neutrophilic leukocytosis was observed in the focus of inflammation. Leukocytes actively phagocytized microorganisms present in the pathological focus. Microscopic fungi of the species *A. flavus*, *A. fumigatus*, *M. species*, and *P. commune* sprouted on Saburo medium from necrotic tissues of the pathological focus. A similar composition of fungal species was obtained by sowing feed samples fed to horses. Microbiological studies of ulcers revealed the growth of two microorganisms, *S. aureus* and *P. vulgaris*, on Baird-Parker agar. On the third day of treatment, compared to the first day, the size of the ulcers decreased by 22.8 %. It is recommended to perform primary surgical treatment of the ulcer, apply PVP iodine spray once a day, and replace the affected feed with high-quality feed to achieve a positive therapeutic effect.

Keywords: horses, mucous membrane ulcers, microscopic studies, treatment

RESUMO

O artigo apresenta os resultados dos estudos de monitoramento das lesões da membrana mucosa em cavalos da raça Trakehner. Com base no exame clínico, foram determinados a localização, o tamanho e o número de úlceras, bem como a reação inflamatória à presença de tecido necrótico. Além do exame clínico, também foram realizados estudos planimétricos para determinar o tamanho das úlceras e a dinâmica de sua redução durante o tratamento com a aplicação de aerossol de iodo PVP. Para determinar a natureza da inflamação no foco da lesão, foram feitos esfregaços da superfície das úlceras. Foram realizados estudos microbiológicos e micológicos de tecidos patológicos e amostras de ração para estabelecer os fatores etiológicos que contribuíram para as úlceras. Verificou-se que o tamanho das úlceras variava de 1 a 6 cm e que elas estavam localizadas nos lábios superior e inferior, tanto do lado direito quanto do esquerdo. A leucocitose neutrofílica foi observada no foco da inflamação. Os leucócitos fagocitaram ativamente os microrganismos presentes no foco patológico. Fungos microscópicos das espécies *A. flavus*, *A. fumigatus*, *M. species* e *P. commune* brotaram em meio Saburo a partir de tecidos necróticos do foco patológico. Uma composição semelhante de espécies de fungos foi obtida com a semeadura de amostras de ração fornecidas a cavalos. Os estudos microbiológicos das úlceras revelaram o crescimento de dois microrganismos, *S. aureus* e *P. vulgaris*, no ágar Baird-Parker. No terceiro dia de tratamento, em comparação com o primeiro dia, o tamanho das úlceras diminuiu em 22,8%. Recomenda-se realizar o tratamento cirúrgico primário da úlcera, aplicar o spray de iodo PVP uma vez ao dia e substituir a ração afetada por ração de alta qualidade para obter um efeito terapêutico positivo.

Palavras-chave: cavalos, úlceras de membrana mucosa, estudos microscópicos, tratamento

* Corresponding author: tzvenig@gmail.com

Submitted: June 24, 2023. Accepted: October 6, 2023.

INTRODUCTION

In Ukraine, horses are used in sports, for hippotherapy, transportation of goods and people, as well as for agricultural and forestry work, especially in mountainous regions where access by automobiles is limited.

The most common oral disease in horses is ulceration of the mucous membranes. The main causes of ulcers in horses' mouths are trauma, autoimmune and neoplastic processes, poor coarse feed, and infection with fungi and bacteria (Easley *et al.*, 2010). There are scientific reports that ulcers next to the first and second premolars and near the corner of the lips are caused by tension in the bit and bridle, which is not affected by the normal displacement of teeth (Tell *et al.*, 2008; Björnsdóttir *et al.*, 2014). In Icelandic horses, the use of a curb bit with a port has been associated with a higher risk of lower jaw branch injuries compared to a snaffle bit or a traditional Icelandic curb bit (Björnsdóttir *et al.*, 2014; Tuomola *et al.*, 2021).

Pain in the horse's mouth is considered a serious welfare problem (Popescu *et al.*, 2014; Tuomola *et al.*, 2019). Conscious perception of pain that occurs in the body as a whole, its role and evaluation through behavior, as well as the sensory function of the horse's oral cavity, are described as a basis for a more detailed assessment of pain in the mouth (Mellor and Beausoleil, 2017; Mellor, 2020).

MATERIALS AND METHODS

Clinical monitoring studies aimed at detecting lesions of the oral cavity were conducted in the Poltava region for nine years (2014-2023). Horses with signs of oral cavity lesions were identified at the Horse farm "Traken" (n=5) in Chutovo village (Kulinich, 2015), and at the Ei-Di equestrian club in Gozhuli village, where a diagnosis of ulceration of the mucous membrane of the lips was established during clinical examination of the animals.

Visual studies were conducted in the following sequence: firstly, a speculum was inserted into the oral cavity of the animal and fixed at the occiput (Figure 1). After that, an examination of the oral cavity was performed. The following were determined: depth of the oral vestibule, color of the mucous membrane, presence of swelling of the mucous membrane (impressions

of teeth along the line of their contact), condition of the salivary gland ducts, and the character of secretions from them. The attachment of the upper and lower lip frenula, lateral restraints of the mucous membrane, were also examined. Subsequently, an examination of the oral cavity proper was performed, considering the color, moisture, turgor, integrity, and the presence of pathological formations (desquamation, erosion, ulcers, neoplasms) of the mucous membrane, as well as the state of the tongue (size, mobility, foldability, and the presence of swelling), the floor of the mouth, and the ducts of the sublingual and submandibular salivary glands. The condition of the tongue frenulum, the shape of the palate, the condition of the mucous membrane of the hard and soft palate, the uvula, and the tonsils were also examined.

Laboratory studies were conducted at the Regional State Laboratory of Veterinary Medicine in the Poltava region. Cytological studies were performed by making smears of imprints from ulcers and staining them using the Romanowsky-Giemsa method. Before taking the smears, the mucous membrane of the animals' oral cavity was rinsed with a solution of boric acid and 5-7 drops of a 1% solution of dycaine were applied to the mucous membrane of the lips (Ostrovsky, 1978). We also conducted mycological studies to detect microscopic fungi in the pathological focus, feed, and bacteriological studies. For the former, cultures were made on Sabouraud agar. Identification of fungal cultures was performed by comparing macroscopic and microscopic features of the experimental cultures with previously described features of fungi (Sutton *et al.*, 2001). Microorganisms present in the pathological material were isolated using the Baird-Parker agar method, and their hemolytic activity was determined on Cetler's blood agar. Identification was carried out according to Bergey's Manual. After performing the initial surgical treatment (removal of purulent-necrotic masses using a swab), PVP iodine spray from the Czech manufacturer Bioveta was sprayed onto the surface of the ulcer from 20-30 cm. In our research, we conducted clinical and planimetric studies to objectively assess changes in the state of the pathological process. To do this, we measured the size of defects on the first, third, and 14th day using a ruler with a division price of 1 mm (DSTU 427-2009).




Figure 1. Preparation of the horse for clinical examination a) pharynx; b) fixation of the pharynx on the animal before examination.

When evaluating clinical changes, the nature of the ulcer surface and the presence of secretions were assessed. The experimental material obtained was processed by the method of variation statistics with determination of arithmetic means (M) and standard deviations (m).

The housing conditions for animals and the methods used in experimental research followed the guidelines set forth in the European Convention for the Protection of Vertebrate Animals Used for Experimental and Other Scientific Purposes (Strasbourg, 1985). The research protocol of the current study was approved by the Ethic Committee of Poltava State Agrarian Academi (Aprobal number 2020/04).

RESULTS AND DISCUSSION

During the dispensary examination of horses at the Chutivsky stud farm "Traken" (n=5), 5 heads with ulcers on the mucous membrane of the lips were detected. In 100% of cases, the lesions were diagnosed in stallions. The appearance of ulcers on the left lateral surface of the lips was diagnosed in the stallion Hodky (Figure 2a). The size of the ulcer on the upper lip was 1.5x2.2 cm, and on the lower lip, it was 4.3x2.7cm. In the stallion Olimp, the appearance of three ulcers on the right lateral surface of the lips was diagnosed. Two of them were about 0.8x0.6 cm

in size, and one was 1.2x0.8cm. In the stallion Piero, during the clinical examination, an ulcer measuring 5.1x6.3cm was found on the left side of the upper lip (Figure 2b). In the stallion Pléro, an ulcer was found on the upper lip in the central part, measuring 7.2x3.6cm. In the stallion Prospekt, ulcers measuring 1.2x1.4cm were found in the corners of the lips. The ulcer had a dirty color, with necrosis of the edges and the presence of purulent exudate under which a wet surface of red color was revealed. Inflammatory swelling and hyperemia around the ulcer were also pronounced. Small ulcers were cleaned of necrotic tissue and purulent exudate, and the appearance of small granulations on the bottom and edges of the ulcer was observed. Along the periphery of the ulcer, scarring and epithelization from the edges were noted. Smears-imprints from the mucous membrane of the lips of sick animals showed an increase in the number of epithelial cells, which were in a state of dystrophy and necrosis.

Uldahl *et al.* (2022) introduced a protocol (Oral Commissure Assessment) for the classification and registration of pathological lesions on the corners of the lips. The precise anatomical location was considered, pigmentations were classified as natural or potentially pathological, and pathological lesions were characterized. 206 horses were examined, only two had bruises or erosions, five had ulcers, and none had bleeding.

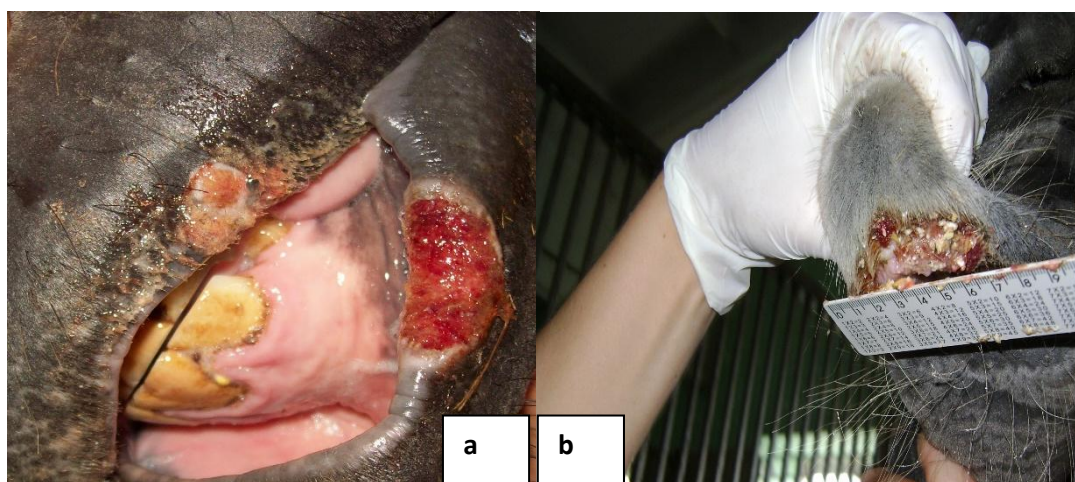


Figure 2. Ulcers: a) on the upper and lower lips on the left side; b) on the upper lip.

We also observed the appearance of neutrophil leukocytosis. The latter were in a state of phagocytosis and actively engulfed

microorganisms present in the pathological focus (Figure 3). Neutrophils on the smear were clustered in amounts ranging from 2 to 10 cells.

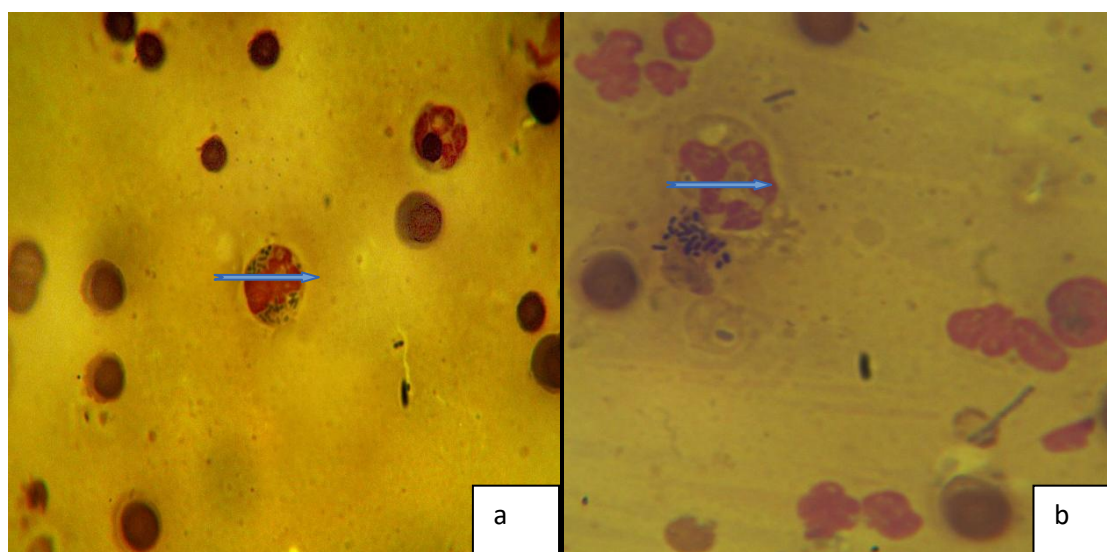


Figure 3. Native smear of horse lip mucosa ulcers (X400), phagocytosis of microorganisms by neutrophil; a) stallion Hodky; b) stallion Piero

In this case, the cellular composition in 5 fields of view under the microscope was as follows: erythrocytes 12 ± 4.3 , neutrophil leukocytes 4.3 ± 2.5 , and epithelial cells 3.5 ± 1.5 .

Samples of necrotic tissue from the surface of ulcers were placed in bacteriological tubes with isotonic sodium chloride solution and were sown in a dense Sabouraud medium in laboratory

conditions. When the culture of the fungus *A. flavus* (Figure 4) grew on Sabouraud's medium, the growth of mycelium was not intensive and was registered from the 4th day. Later, on the fifth day, an increase in mycelium above the surface of the nutrient medium was noted. By the fifth day, the mycelium had acquired a more intense coloration and darkened.

Lip lesions...

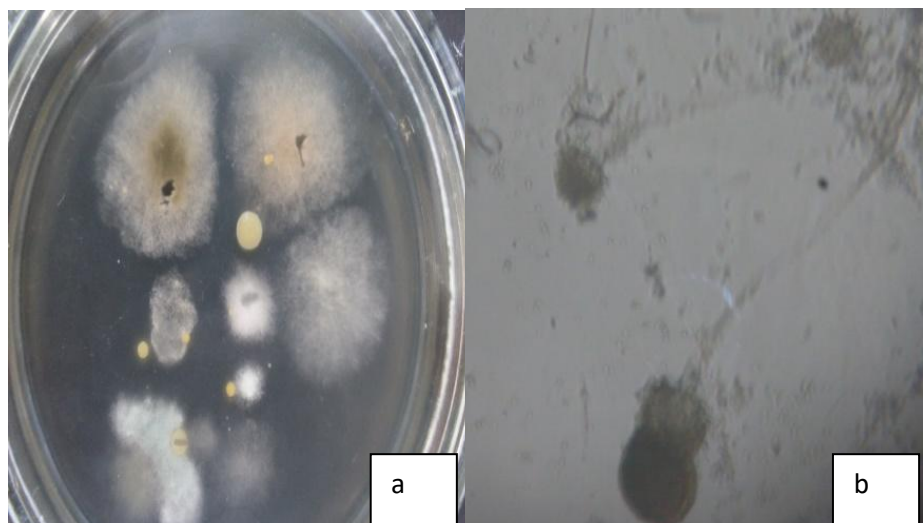


Figure 4. Mycological studies. a) growth of *M. species* and *A. flavus* on Sabouraud medium; b) mycelium of *A. flavus* (X150)

When growing the mycelium of the *A. fumigatus* fungus on Sabouraud agar, the first signs of development in the form of semi-transparent formations were observed after 8 hours. After two days, the appearance of a whitish fluffy coating was observed. On the fourth day, the growth of a massive colony of round shapes with a greenish-blue tint in the center and a whitish border on the periphery was recorded. There are descriptions of liver lesions in horses caused by *A. Fumigatus*, as well as reports of infections of feed with this type of fungus, such as hay, silage, oats, and concentrated feed (Caloni and Cortinovi, 2011). Randleff-Rasmussen *et al.* (2017) describe the non-classical detection of a skin mycetoma of the lateral wing of the right nostril in a 16-year-old Fjord stallion with suspected dysfunction of the intermediate part of the pituitary gland, in which a painless, hard new growth was found around the lateral wing of the right nostril and lip. Cytological examination of the formation showed marked pyogranulomatous inflammation, and histopathological examination revealed a fungal mycetoma. The fungal culture was identified as *Aspergillus terreus*. The authors achieved positive results after 5 months of treatment with pergolide, potassium iodide administered orally to the animal (Randleff-Rasmussen *et al.*, 2017).

In addition, growth of fungi of the species *Mucor* was observed. The growth of the fungus was

noted after 36 hours in the form of a white fluffy coating. After three days, the formation of a white voluminous fluffy colony with a strong mycelium was recorded. On the fifth day, the mycelium became tall, gray, and had an airy structure in the form of a canopy. Imogen Johns (2011) reports the fact of the sowing of *Mucor* fungi from the conjunctiva of horses. Abdullah (2022) identified the growth of *Mucor indicus* fungi in a mare with inflammation of the nasal cavity.

The growth of the *P. expansum* fungus was characterized by the appearance of green mycelium on the surface of the medium from the third day. The colonies of the *P. commune* fungus grew in the form of radial, fluffy, blue-gray colonies, with orange-brown on the reverse side of the cup; their edge thickened more towards the center. According to the analysis of research results, it was found that in cases of ulcerative lesions of the lips, microscopic fungi were more often detected in the form of associations.

In order to identify the source of mycotic pathogens, a study of feeds that are included in the diet of horses was conducted. Samples of feed were sown on Sabouraud's medium and incubated at 25°C for five days. Analysis of the results showed that the species composition was

practically identical to that isolated from the ulcerations on the lips.

During bacteriological studies, two microorganisms were isolated by the Baird-Parker agar method: *S. aureus* and *P. vulgaris*. Both species grew on blood agar but did not produce hemolysis (Figure 5).

After removal of purulent-necrotic masses using a tampon, PVP-Iodine spray (PVP YOD spray)

from the Czech manufacturer AO "Biowet" was aerosolized onto the surface of the ulcer from 20-30 cm (Fig. 5a). In our study, for an objective assessment of changes in the state of the pathological process during treatment, clinical and planimetric studies were conducted. For this, the defects were measured using a ruler on the first, third, and 14th day. Clinical changes were evaluated by the character of the surface of the ulcers and the presence of secretions (Figure 5b).

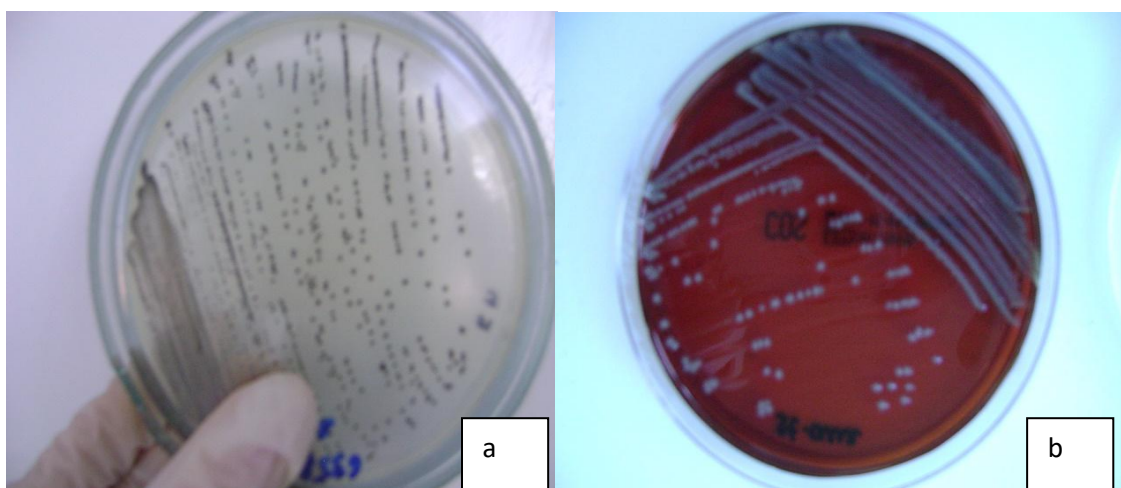


Figure 5. Microbiological studies a) Growth of *P. vulgaris* on Baird-Parker agar b) Growth of *S. aureus* on Zeissler blood agar

The area of the ulcer surface in animals during treatment significantly decreased (Table 1). Thus, on the third day relative to the initial data, the average reduction in the defect was 22.8%. Accordingly, on the 14th day, the reduction of the defect relative to the initial data was 4.2

times, and 3.3 times relative to the indicators on the third day. Clinically, starting from the third day, a decrease in the defect and the disappearance of signs of purulent exudation were observed. In the future, epithelialization was noted creeping onto the surface of the ulcer.

Table 1. Dynamics of wound surface area in the treatment of horses with lip ulcers, cm², M±m

Indicators		Defect size
Day of Treatment	1	14.5±0.72
	3	11.2±0.36

While studying a 6-month-old colt named "Gai" at the AD equestrian club in Gozhuli village, bilateral lesions of the lips on the right side were identified. Accordingly, the ulcers had a pink color with a gray border on the periphery. In some places, the accumulation of gray necrotic tissue was noted on the surface. On the upper lip on the right side, one large lesion was found, measuring 8.2 x 4.1cm, and on the lower lip, there were two separate lesions of regular shape measuring 6.2 x 2.2cm and less than 5.4 x 2.1cm.

On the left side, a lesion measuring 5.4 x 2.6cm was found on the upper lip, and two oval-shaped lesions on the lower lip merged into one and measured 5.6 x 1.8cm.

Cytological examination of a native smear of the mucous membrane of the affected lips revealed neutrophil infiltration. It was found that neutrophils were at different stages of maturation: promyelocyte, segmented neutrophil, phagocytosis of microorganisms by neutrophils.

Nicolas J. Vos recommends using iodine solutions for flushing after surgical treatment of lip ulcers in ponies caused by *Actinomyces* fungi. Dixon & Dacre (2005) report successful treatment of ulcers caused by stomatitis with diluted iodine solution. These reports are consistent with the use of iodine solutions in our studies.

CONCLUSION

The prevalence of lip ulcers in horses has been established through cytological and mycological research, as well as treatment of affected animals. The effectiveness of the procedures performed was determined based on clinical and planimetric data analysis.

It has been proven that clinically, ulcers had a dirty color, with necrosis at the edges, the presence of purulent exudate under which revealed a wet surface of red color. Inflammatory swelling and hyperemia around the ulcer were also pronounced.

Mycological studies of samples of necrotized tissue identified the presence of microscopic fungi species such as *A. flavus*, *A. fumigatus*, *Mucor* species, *P. expansum*, *P. commune*, and bacterial cultures *S. aureus* and *P. vulgaris*.

Removing the affected feed from the diet, replacing it with quality feed, and subsequent treatment of sick horses with aerosol application of the PVP YOD spray from the Czech manufacturer AO "Biovet" was found to be quite effective, as the area of the wound surface in animals decreased 4.2 times by the end of the treatment.

REFERENCES

ABDULLAH M. Black Fungi in Arabian Horses: scanning electron microscopy study of cutaneous equine mucormycosis caused by *mucor indicus* for the first time in Eastern Province, Saudi Arabia. *Am. J. Vet. Sci.*, v.73, p.36-51, 2022.

BJÖRNSDÓTTIR, S.; FREY, R.; KRISTJANSSON, T.; LUNDSTRÖM T. Bit-related lesions in Icelandic competition horses. *Acta Vet. Scand.*, v.56, p.40, 2014.

CALONI, F.; CORTINOVIS, C. Toxicological effects of aflatoxins in horses. *Vet. J.*, v.188, p.270-273, 2011.

DIXON, P.M.; DACRE, I. A review of equine dental disorders. *Vet. J.*, v.169, p.165-187, 2005.

EASLEY, J.; TREMAINE, W.H.; DIXON, P.; SCHUMACHER, J. *Dental and oral examination. Equine dentistry.* 2.ed. Philadelphia: Elsevier Saunders, 2010.

EEC. Council Directive 86/609/EEC of 24 November 1986 on the approximation of laws, regulations and administrative provisions of the Member States regarding the protection of animals used for experimental and other scientific purposes. *Official Journal of the European Communities*, L358, p.1-29, 1986.

JOHNS, I.C.; BAXTER, K.; BOOLER, H.; HICKS, C.; MENZIES-GOW, N. Conjunctival bacterial and fungal flora in healthy horses in the UK. *Vet. Ophthalmol.*, v.14, p.195-199, 2011.

KULINICH S.M. Distribution, diagnosis and treatment of horses with ulcerative lesions of the lips on the basis of equestrian sports complex SOR «Chutovsky stud «Trakia». *Bull. Sumy Natl. Agrar. Univ. Vet. Med.*, v.7, p.195-199, 2015.

MELLOR, D.J. & BEAUSOLEIL, N.J. Equine welfare during exercise: an evaluation of breathing, breathlessness and bridles. *Animals*, v.7, p.41, 2017.

MELLOR, D.J. Pre-competition oral findings in danish sport horses and ponies competing at high level. *Animals*, v.10, p.572, 2020.

OSTROVSKY, N.S. Cytological method of diagnostics of eye diseases of cattle. Collection of scientific works of the Don Agricultural Institute. *Persianovka*, v.13, p.37-41, 1978.

POPESCU, S.; DIUGAN, E.A.; SPINU, M. The interrelations of good welfare indicators assessed in working horses and their relationships with the type of work. *Res. Vet. Sci.*, v.96, p.406-414, 2014.

RANDLEFF-RASMUSSEN, P.K.; MOSCA, M.; DESJARDINS, I. Successful medical treatment of an *Aspergillus terreus* mycetoma of the nostril/lip in a 16-year-old Fjord pony gelding with pituitary pars intermedia dysfunction. *Vet. Dermatol.*, v.28, p.629, 2017.

SUTTON, D.; FOTHERGILL, A.; RINALDI, M. The Determinant of pathogenic and conditionally pathogenic fungi. *World*, n.468, 2001.

TELL, A.; EGENVALL, A.; LUNDSTRÖM, T.; WATTLE, O. The prevalence of oral ulceration in Swedish horses when ridden with bit and bridle and when unriden. *Vet. J.*, v.178, p.405-410, 2008.

TUOMOLA K.; MAKI-KIHNIÄ N.; KUJALA-WIRTH M. Risk factors for bit-related lesions in Finnish trotting horses. *Equine Vet. J.*, v.53, p.1132-1140, 2021.

TUOMOLA, K.; MÄKI-KIHNIÄ, N.; KUJALA-WIRTH, M.; MYKKÄNEN, A.; VALROS, A. Oral lesions in the bit area in Finnish Trotters after a race: Lesion evaluation, scoring, and occurrence. *Front. Vet. Sci.*, v.6, p.206, 2019.

ULDAHL, M.; BUNDGAARD, L; DAHL, J.; CLAYTON, H.M. Assessment of skin and mucosa at the equine oral commissures to assess pathology from bit wear: the Oral Commissure Assessment Protocol (OCA) for analysis and categorisation of oral commissures. *Animals*, v.12, p.643, 2022.