



## PREVALENCE AND CO-INFECTION OF *BARUSCAPILLARIA* GENUS (NEMATODA, CAPILLARIIDAE) IN DOMESTIC GEESE IN UKRAINE

Yevstafieva, V.<sup>1</sup>, Yeresko, V.<sup>1</sup>, Melnychuk, V.<sup>1</sup>, Bakhur, T.<sup>2</sup>

<sup>1</sup>Department of Parasitology and Veterinary-Sanitary Examination  
Institute of Veterinary Medicine, Poltava State Agrarian Academy  
Skovorody Str., 1/3, 36003, Poltava

<sup>2</sup>Department of Parasitology and Pharmacology  
Bila Tserkva National Agrarian University  
Soborna Sq., 8/1, 09100, Bila Tserkva, Kyiv region  
Ukraine

evstva@ukr.net; fly\_13@ukr.net

### ABSTRACT

New data about the fauna of nematodes of *Baruscapillaria* genus have been obtained which show that they parasitize domestic geese in the Poltava region of the Ukraine. It has been established that the species composition of *Capillariidae* is represented by two species—*B. anseris* (Madsen, 1945, Moravec, 1982) and *B. obsignata* (Madsen, 1945, Moravec, 1982). For the first time in the Ukraine, parasitisation with non-specific geese species of *Capillariidae* family, *B. obsignata*, have been substantiated. It was found that capillariosis of geese was more frequent in the co-invasions of the birds' digestive channel; the prevalence of invasion was 41.97 %. According to the results of helminthological dissection and identification of isolated pathogens, 40 varieties

of co-invasions were found, where nematodes of the *Baruscapillaria* genus were combined with cestodes of two species: *Drepanidotaenia lanceolata* (Bloch, 1782) and *Tschertkovilepis setigera* (Froehlich, 1789), as well as with nematodes of four other species: *Amidostomum anseris* (Zeder, 1800), *Trichostrongylus tenuis* (Mehlis, 1846), *Heterakis gallinarum* (Schrank, 1788) and *Heterakis dispar* (Schrank, 1790). Most often, we recorded capillariosis as a part of two- (prevalence—17.75 %) and three-component (11.75 %) co-invasions, and the main coexisting helminths of *Capillariidae* from *Baruscapillaria* genus were nematodes *A. anseris* (prevalence 22.78 %) and *H. dispar* (14.15 %).

**Key words:** *Anser domesticus*; associative course; capillariosis; co-invasions prevalence

## INTRODUCTION

Geese breeding is a promising and in-demand poultry industry worldwide, particularly in the Ukraine. This is due to the fact that geese, unlike other farmed poultry, are the least demanding concerning growing and confining conditions. These birds are characterized by their precocity, as well as providing a wide range of products for the food, perfume, pharmaceutical and light industries [4, 6, 7, 11].

One of the main reasons restricting the development of the geese breeding is the problem of helminthoses of the digestive canal, in particular capillariidoses, which cause significant economic losses to the farms. Due to the parasite invasions, young geese are lagging behind in growth and development, their preservation is reduced, as well as the productivity and breeding value of adult birds [3, 5, 8, 12].

Scientists have pointed out the widespread prevalence of geese capillariosis in different countries of the world, where invasion occurs mainly as part of the associated parasitic diseases of the digestive tract of birds. In Japan, in 15 species of birds of the *Anseriformes* order, three species of *Capillariidae* parasites have been identified: *Eucoleus contortus*, *Capillaria (C.) anatis*, *Baruscapillaria (B.) mergi*. The prevalence of invasion ranged from 8.89 to 100 %, and the intensity (according to the results of post-mortem autopsy) from 1 to 55 specimens of helminths per bird [18]. After studying the faeces of grey wild geese in Austria, scientists found that the prevalence of capillariosis invasion was low compared to other helminthoses and protozoan parasitosis and reached only 0.2 % [15].

At the same time, in the Czech Republic, two species of *Capillariidae* have been identified on broiler geese farms: *C. caudinflata* (prevalence 0.2 %) and *C. obsignata* (7.7 %). Moreover, *Capillariidae* in birds have been parasitized in associations with: *Notocotylus attenuatus*, *Apatemon gracilis*, *Cotyrlus cornutus*, *Hypoderaeum conoideum*, *Retinometra longicirrosa*, *Drepanidotaenia lanceolata*, *Sobolevicanthus fragilis*, *Diorchis stefanskii*, *Microsomacanthus microsoma*, *Dilepis undula*, *Amidostomum anseris*, *Trichostrongylus tenuis*, *Ganguleterakis dispar* and *Heterakis gallinarum*. The authors diagnosed two-component (in 29.7 % of poultry), three-component (7.8 %) and four-component (1 %) invasions [2]. In Germany, researchers have found that in grey geese, the causative agent of capillariosis was associated with nematodes of *Amidostomum* and *Trichostrongylus* ge-

nus, as well as the protozoa of *Eimeria* genus [16]. Therefore, the study of *Capillariidae* fauna which parasitize domestic geese in Ukraine, as well as the peculiarities of these nematodes' parasitizing the body of birds is a relevant area of research.

## MATERIALS AND METHODS

This research was conducted during 2016—2018 in the laboratory of the Department of Parasitology and Veterinary-Sanitary Examination at the Poltava State Agrarian Academy and under the conditions of 5 poultry enterprises and 132 small private farms in the Poltava region of the Ukraine (Velykobahachanskyi, Hadiatskyi, Hlobynskyi, Dykanskyi, Zinkivskyi, Kotelevskyi, Lubenskyi, Lokhvytskyi, Myrhorodskyi, Shyshatskyi districts).

In order to determine the species composition of pathogens, we performed autopsies of geese's digestive organs canals. The helminths were collected by the method of complete helminthological dissection of birds' digestive organs canals [13]. The collected helminths were fixed in 70 % ethyl alcohol. For the differentiation of nematodes, they were preliminarily placed in lactophenol, and the cestodes were stained with acetocarmine. A total of 417 organs of the digestive tracts (glandular and muscle parts of the stomachs, small intestine, large intestine, oesophagus, ingluvies) of geese were examined; large Gray, Danish Legart, Gorkovskaya, Mirgorodska, as well as mixed breeds.

The occurrence of helminth agents in the geese was indicated by the prevalence rate (%). The identification of helminths' species was carried out by a qualifier [10, 14]. Microphotographs were obtained by means of a digital camera and a MikroMed 5Mpix (China) microscope using a  $\times 10$ ,  $\times 40$  lens and a  $\times 10$  photo eyepiece.

## RESULTS

According to the results of this parasitological investigation, it was found that capillariosis was a common nematode invasion of geese in the Ukraine. The average prevalence of capillariosis invasion of geese under the conditions of poultry farms in the Poltava region reached 57.79 % with an invasion intensity of  $39.55 \pm 2.27$  specimens per bird. The indicators of the prevalence of the geese nematodes of *Ba-*

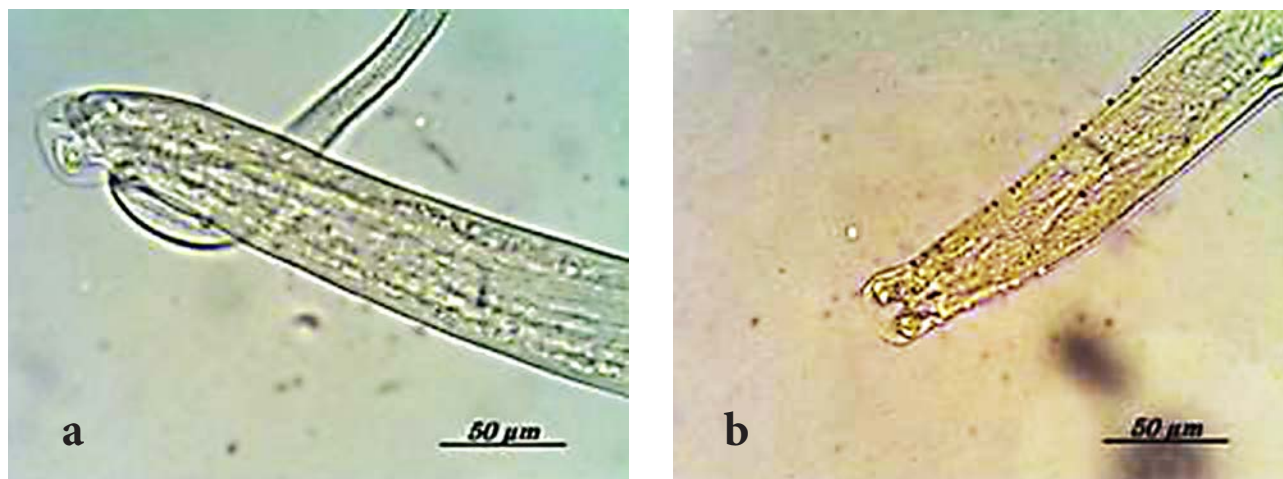


Fig. 1. Caudal end of ♂ *Baruscapillaria* genus nematodes':  
a—*B. anseris*; b—*B. obsignata*

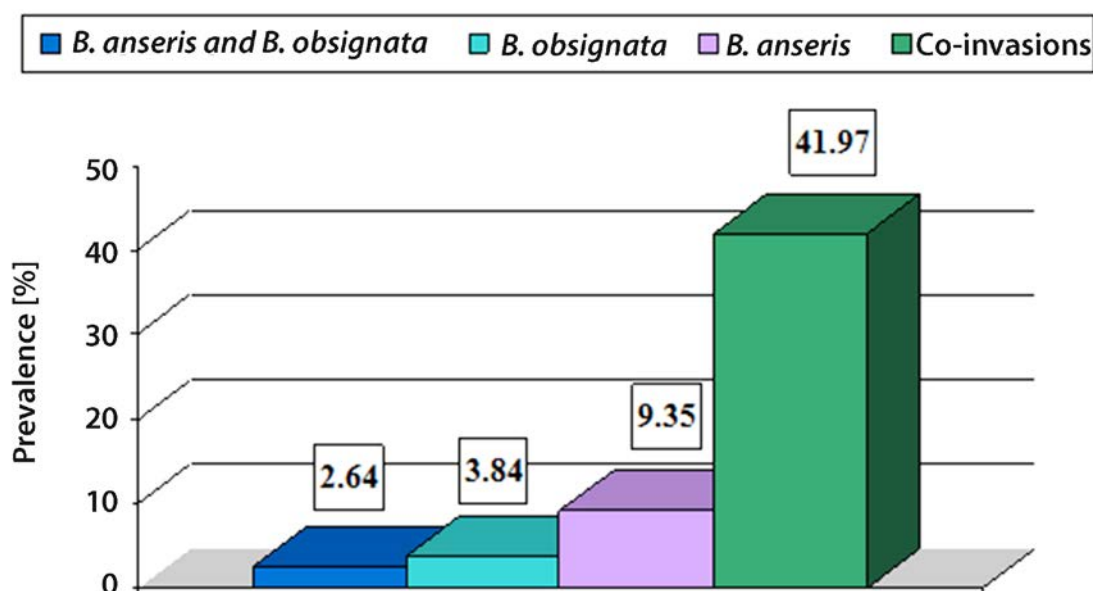


Fig. 2. Indicators of the prevalence [%] of *Baruscapillaria* genus in the composition of mono- and co-invasions

*ruscapillaria* genus (*Nematoda*, *Capillariidae*) in different areas showed slight fluctuations and ranged from 51.22 % (Dykanskyi district) to 68.98 % (Shyshatskyi district). It was also observed that *Capillariidae* fauna was represented by two species—*B. anseris* (Madsen, 1945, Moravec, 1982) (Fig. 1a) and *B. obsignata* (Madsen, 1945, Moravec, 1982) (Fig. 1b). The predominant species was *B. anseris* with the average prevalence in geese reaching 46.76 %, and the intensity of 38.3 specimens per bird. At the same time, the number of *B. obsignata* nematodes was much lower than

that of *B. anseris*, with a prevalence of 23.98 % and the intensity of 15.7 specimens per bird.

It was found that the geese's capillariosis often had an associative course of a co-invasion of the geese's digestive canal (prevalence 41.97 %). Mono-invasion capillariosis was diagnosed less frequently (15.83 %); of this 2.64 % of the birds showed simultaneous parasitisation of capillariid nematodes of both species (*B. anseris* and *B. obsignata*) while 9.35 % of the birds were parasitized only with *B. anseris* and 3.84 % only with *B. obsignata* (Fig. 2).

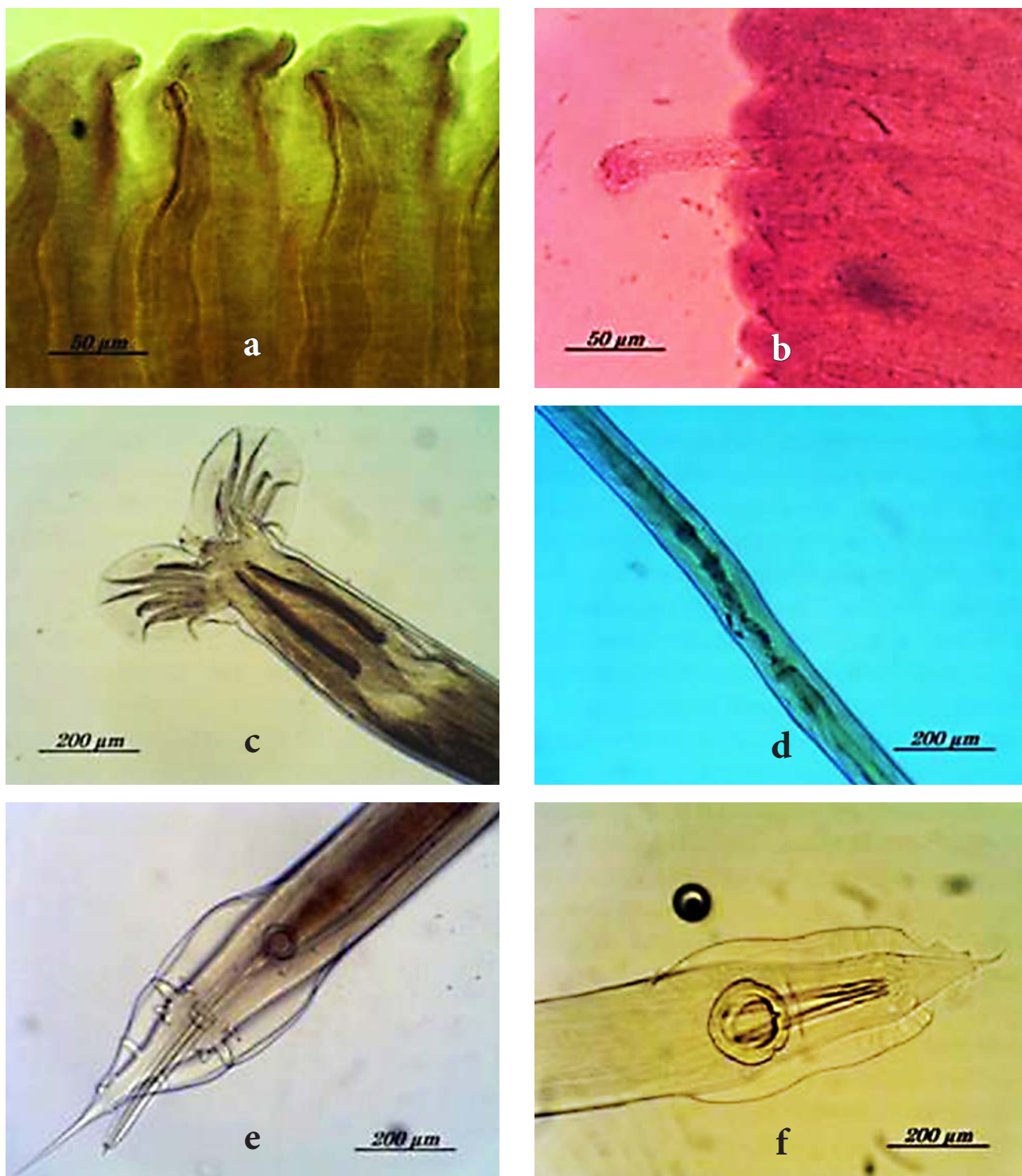


Fig. 3. Species composition of coexisting nematodes of Baruscapillaria genus in geese:  
a—cirrus bursa in hermaphroditic proglottids of *D. lanceolata*; b—outward cirrus in hermaphroditic proglottid of *T. setigera*;  
c—caudal end of ♂ *A. anseris*; d—vulvae area of ♀ *T. tenuis*; e—caudal end of ♂ *H. gallinarum*; f—caudal end of ♂ *H. dispar*



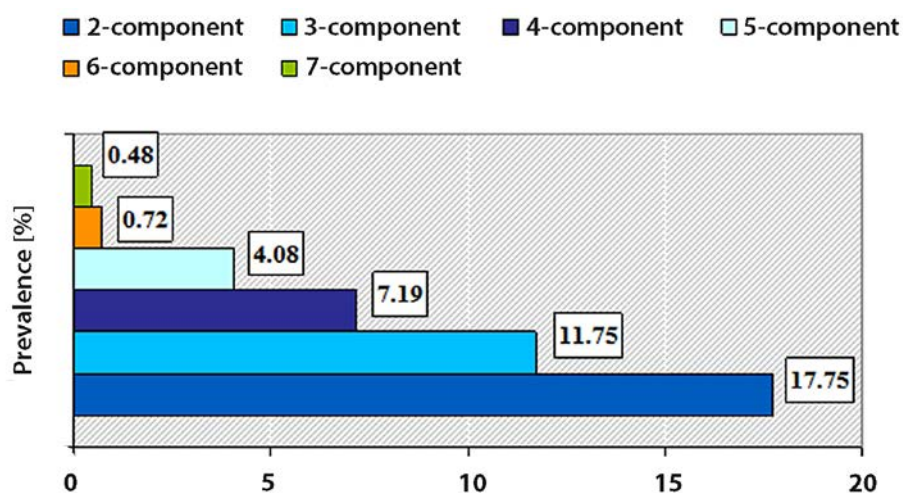


Fig. 4. Prevalence indicators of various components of co-invasions in geese during parasitisation with *Baruscapillaria* genus's nematodes

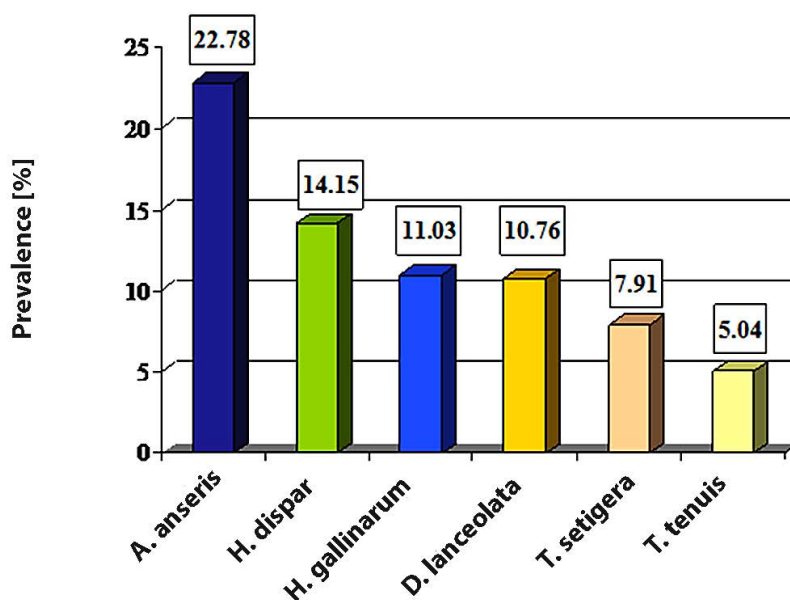


Fig. 5. Species composition of cohabitants of *Baruscapillaria* genus's nematodes in geese's digestive canal co-invasions

In general, 40 varieties of co-invasions were found, where nematodes of the *Baruscapillaria* genus were combined with cestodes of two species: *Drepanidotaenia lanceolata* (Bloch, 1782) (Fig. 3a) and *Tschertkovilepis setigera* (Froehlich, 1789) (Fig. 3b), as well as with nematodes of four species: *Amidostomum anseris* (Zeder, 1800) (Fig. 3c), *Trichostrongylus tenuis* (Mehlis, 1846) (Fig. 3d), *Heterakis gallinarum* (Schränk, 1788) (Fig. 3e) and *Heterakis dispar* (Schränk, 1790) (Fig. 3f).

The prevalence of geese's capillariosis in combination with several species of helminths is presented in Fig. 4. As can be seen, the most common were 2- and 3-component co-invasions.

Among the two-component co-invasions, the association of *Baruscapillaria* genus's nematodes and *A. anseris* (5.52 %) were most commonly diagnosed. Such associations of capillariid were less common: with *H. dispar* (3.59 %), *T. setigera* (2.88 %), *H. gallinarum* (2.16 %), *T. tenuis* (1.92 %), *D. lanceolata* (1.68 %).

Among three-component co-invasions, there were established associations of capillariid with: *A. anseris*, *T. tenuis*, *H. gallinarum*, *H. dispar*, *D. lanceolata*, *T. setigera* in different combinations. The prevalence ranged from 0.24 to 1.92 %.

Four-component co-invasions involved the following associations: *B. anseris*, *B. obsignata*, *A. anseris* and *T. setigera* (1.92 %); *B. anseris*, *A. anseris*, *H. dispar* and *D. lanceolata* (1.44 %); *B. anseris*, *B. obsignata*, *H. gallinarum* and *D. lanceolata* (1.19 %); *B. anseris*, *B. obsignata*, *A. anseris* and *D. lanceolata* (0.96 %); *B. anseris*, *B. obsignata*, *A. anseris* and *H. gallinarum* (0.96 %); *B. anseris*, *B. obsignata*, *A. anseris* and *H. dispar* (0.24 %); *B. anseris*, *B. obsignata*, *H. dispar* and *H. gallinarum* (0.24 %); *B. anseris*, *A. anseris*, *H. dispar* and *T. setigera* (0.24 %).

Five-component co-invasions were represented by four varieties of associations: *B. anseris*, *B. obsignata*, *H. dispar*, *A. anseris* and *D. lanceolata* (1.92 %); *B. anseris*, *A. anseris*, *H. dispar*, *H. gallinarum* and *T. setigera* (1.68 %); *B. anseris*, *B. obsignata*, *H. dispar*, *H. gallinarum* and *D. lanceolata* (0.24 %), as well as *B. obsignata*, *A. anseris*, *H. dispar*, *H. gallinarum* and *T. setigera* (0.24 %).

Six- and seven-component co-invasions consisted of: *B. anseris*, *B. obsignata*, *A. anseris*, *H. dispar*, *H. gallinarum* and *D. lanceolata* (0.72 %), *B. anseris*, *B. obsignata*, *A. anseris*, *H. dispar*, *H. gallinarum*, *T. tenuis* and *D. lanceolata* (0.24 %), as well as *B. anseris*, *B. obsignata*, *A. anseris*, *H. dispar*, *T. tenuis*, *D. lanceolata* and *T. setigera* (0.24 %).

It was determined that the main cohabitants of *Baruscapillaria* genus's nematodes in geese's bodies were nematodes *A. anseris* (prevalence 22.78 %) and *H. dispar* (14.15 %). A smaller percentage was determined for capillariid associations with *H. gallinarum*, *D. lanceolata*, *T. setigera* and *T. tenuis* (Fig. 5).

It was observed that capillariosis caused by *Baruscapillaria* genus's nematodes was a common invasion of domestic geese in Ukraine; it mainly occurs as a part of co-invasions together with pathogens of cestodoses and nematodoses of the birds' intestinal canal.

## DISCUSSION

Studies have shown that nematodes of *Baruscapillaria* genus are common parasites of domestic geese in Ukraine. The avian affection rate averaged 57.79 % and capillariid

fauna was represented by two species: *B. anseris* and *B. obsignata*. Significant distributions of capillariid parasites among domestic and wild waterfowl birds in Poland, Japan, Nigeria, India have been confirmed by a number of authors [1, 5, 8, 9].

We also found that capillariosis pathogens of birds occurs more frequently in the form of co-invasions (prevalence 41.97 %) together with cestodes (*Drepanidotaenia lanceolata*, *Tschertkovilepis setigera*) and nematodes (*Amidostomum anseris*, *Trichostrongylus tenuis*, *Heterakis gallinarum*, *Heterakis dispar*) of geese's digestive tract. In total, 40 varieties of co-invasions were isolated, where nematodes of *Baruscapillaria* genus were present in association with two to seven helminths. Moreover, with the increase in the number of parasites in associations, the prevalence was gradually reduced from 17.75 % (two-component) to 0.48 % (seven-component). In our opinion, this is due to the antagonism of the individual parasites and the heavy strain on the organism of birds that can lead to their death. Similar data indicating a decrease in prevalence with an increasing number of parasites in co-invasion were reported [2].

It has been shown that nematodes of *Baruscapillaria* genus most often coexist with *A. anseris* and *H. dispar*. We rarely diagnosed capillariid associations with *H. gallinarum*, *D. lanceolata*, *T. setigera* and *T. tenuis*. Scientists attributed this dependence to the fact that helminth associations that are localized in different organs (muscular stomach, small and large intestines) do not compete with each other and are therefore more frequently observed. At the same time, when locating nematodes of different species in one organ (small intestine), their antagonism was noted, which was manifested by a decrease in the number of parasites [17].

The data obtained make it possible to increase the effectiveness of planning measures for the control and prevention of capillariosis in domestic geese, taking into account the peculiarities of parasitisation with nematodes from the *Baruscapillaria* genus.

## CONCLUSIONS

Two species from the genus *Capillaria* were isolated from domestic geese (*Anser anser dom.*) in Ukraine: *Baruscapillaria anseris* (prevalence 46.76 %) and *Baruscapillaria*

*obsignata* (23.98 %). According to the results of helminthological dissections, the average prevalence of *Baruscapillaria* genus nematodes was 28.72 %. The features of *Capillaria nematodes* in geese are characterized mainly by the formation of two- (prevalence 17.75 %) and three-component (11.75 %) parasitic associations, where *Baruscapillaria* genus nematodes coexist with cestodes: *D. lanceolata* and *T. setigera*, as well as nematodes: *A. anseris*, *T. tenuis*, *H. gallinarum* and *H. dispar*. And most often, capillariid helminths parasitize as co-invasions together with *A. anseris* and *H. dispar*; the prevalence reaching 22.78 % and 14.15 %, respectively.

## REFERENCES

1. Adejinmi, J. O., Oke, M., 2011: Gastro-intestinal parasites of domestic ducks (*Anas platyrhynchos*) in Ibadan Southwestern Nigeria. *Asian J. Poultry Sci.*, 5, 46—50. DOI: 10.3923/ajpsaj.2011.46.50.
2. Busta, J., 1980: Helminths in broiler geese fattened in runs. *Vet. Med.*, 25, 12, 717—723.
3. Cervantes-Rivera, K., Villagómez-Cortés, J. A., Arroyo-Lara, A., Landín-Grandvallet, L., 2016: A diagnostic survey of gastroenteric helminths in backyard poultry of a rural village in Mexican tropics. *J. Agric. Biol. Sci.*, 11, 12, 463—469.
4. Chang, S. C., Lin, M. J., Fan, Y. K., Lee, T. T., 2016: Effects of lighting intensity on growth and reproductive performance of breeder geese. *J. Appl. Poultry Res.*, 25, 3, 315—321. DOI: 10.3382/japr/pfw009.
5. Hamadani, H., Khan, A. A., Wani, Z. A., Jalal, H., Bihaqi, S. J. A., Mir, M. S., 2017: Parasitic profile of domestic geese of Kashmir. *Int. J. Livestock Res.*, 7, 5, 129—133. DOI: 10.5455/ijlr.20170409094535.
6. Islam, M. F., Mia, M. M., Rahman, M. A., Bhowmik, N., 2016: Morphometric, productive and reproductive traits of indigenous goose of Bangladesh. *Anim. Genet. Res.*, 59, 37—45. DOI: 10.1017/S2078633616000254.
7. Ivko, I. I., Riabinina, O. V., Melnyk, O. V., 2010: Ways to improve the efficiency of domestic goose breeding. *Effective Poultry Farming*, 11, 71, 33—40.
8. Kornaś, S., Basiaga, M., Kowal, J., Nosal, P., Wierzbowska, I., Kapkowska, E., 2015: Zatorska goose—a subject of parasitological research. *Ann. Parasitol.*, 61, 4, 253—256. DOI: 10.17420/ap6104.15.
9. Nakamura, S., Asakawa, M., 2001: New records of parasitic nematodes from five species of the Anseriformes in Hokkaido, Japan. *J. Zoo Wildlife Med.*, 6, 27—33. DOI: 10.2478/s11687-009-0023-x.
10. Ryzhikov, K. M., 1967: *The Determinant of Helminths of Domestic Waterfowl* (In Russian). Nauka, Moscow, 262 pp.
11. Shi, Z. D., Tian, Y. B., Wu, W., Wang, Z. Y., 2008: Controlling reproductive seasonality in the geese: a review. *World's Poultry Sci. J.*, 64, 3, 343—355. DOI: 10.1017/S0043933908000081.
12. Shutler, D., Alisauskas, R. T., McLaughlin, J. D., 2012: Associations between body composition and helminths of lesser snow geese during winter and spring migration. *Int. J. Parasitol.*, 42, 8, 755—760. DOI: 10.1016/j.ijpara.2012.05.008.
13. Skrjabin, K. I., 1928: *The Method of Complete Helminthological Autopsy of Vertebrates, Including Humans* (In Russian). Moscow State University, Moscow, 45 pp.
14. Skrjabin, K. I., Shikhobalova, N. P., Orlov, I. V., 1957: *Trichocephalids and Capillariids of Animals and Man and the Diseases Caused by them. The Essentials of Nematodology* (In Russian). Russian Academy of Sciences, Moscow, 263—387.
15. Wascher C. A. F., Bauer, A. C., Holtmann A. R., Kotrschal K., 2012: Environmental and social factors affecting the excretion of intestinal parasite eggs in graylag geese. *Behav. Ecol.*, 23, 6, 1276—1283. DOI: 10.1093/beheco/ars113.
16. Woog F., Maierhofer J., Haag H., 2011: Endoparasites in the annual cycle of feral Greylags Anser. *Wildfowl*, 61, 164—179.
17. Yevstafieva V. A., Melnychuk V.V., Yeresko V. I., Lukyanova G.A., Gurenko I. A., 2018: Species composition and distribution of helminths in domestic goose (*Anser dom.*) population. *Vet. Med. J.*, 10, 34—39.
18. Yoshino, T., Uemura, J., Endoh, D., Kaneko, M., Osa, Y., Asakawa, M., 2009: Parasitic nematodes of anseriform birds in Hokkaido, Japan. *Helminthologia*, 46, 2, 117—122. DOI: 10.2478/s11687-009-0023-x.

Received August 28, 2019

Accepted January 30, 2020